

Long-term balloon indwelling technique for the treatment of single benign biliary stricture

Sung-Joon Park 
Hwan Hoon Chung 
Seung Hwa Lee 
Sung Beom Cho
Yun Hwan Kim 
Tae-Seok Seo 
Myung Gyu Song 

ABSTRACT

We aimed to evaluate the feasibility and safety of long-term balloon indwelling technique for the treatment of single benign biliary stricture. Five patients with single benign biliary stricture were included from December 2014 to November 2016. The patients were three men and two women with a mean age of 50 years (range, 30–65 years). A balloon catheter was inserted into the drainage catheter and emerged through the side hole of the catheter so that the balloon and drainage catheters could be placed together at the stricture site. Follow-up fluoroscopic examination was performed at least once every 2 weeks to evaluate the adequacy of expansion and location of the balloon. The balloon was reinflated at each session, and then removed after an approximately two-month indwelling period. The catheters used were 10–16 French and the diameter of indwelling balloons were 4–8 mm. The primary technical and clinical success rates were 100%. Maintenance of the balloon location was achieved in 25 of 26 follow-up fluoroscopic examinations (mean, 5.2 times per patient) with a rate of 96.1%. The mean follow-up period after successful removal of the balloon was 542.2 days (range, 93–1042 days), and there were no recurrences in the five cases. The long-term balloon indwelling technique is a good way to induce maximal dilatation at the stricture site without large diameter skin and subcutaneous tract dilatation and can be successfully used for single benign biliary stricture.

Several long-term indwelling interventional treatments for benign biliary stricture have been developed. Choo et al. (1) proposed balloon dilatation and large profile catheter maintenance method for benign biliary stricture. However, this method has limitations in that dilatation of skin and subcutaneous tissues must be as large as the diameter of the catheter for sufficient dilatation at the benign biliary stricture site. Skin and subcutaneous tract dilatation is usually very painful for patients and requires multiple sessions for sufficient dilatation. Gwon et al. (2) presented a dual catheter placement technique. This method can dilate the stricture site to a wider diameter than the previous single large profile catheter maintenance method, but still requires large diameter subcutaneous tract dilatation.

In this study, we evaluated a long-term balloon indwelling technique that is able to induce larger diameter dilatation at the target benign biliary stricture site while performing smaller skin and subcutaneous dilatation than the previously described methods.

Technique

Patients

The institutional review board approved this retrospective study and waived informed consent. From December 2014 to November 2016, five single benign biliary stricture patients at our institution were treated with the long-term balloon indwelling technique. Patients were three men and two women with a mean age of 50 years (range, 30–65 years). The strictures of three cases were treated after removing combined intrahepatic duct stones, and the other two were not accompanied by stones.

The benign biliary stricture site and presumed cause of biliary stricture for each patient are summarized in Table 1. All patients had undergone percutaneous transhepatic biliary drainage (PTBD) procedure.

From the Department of Radiology (S.P., H.H.C., chungmic@korea.ac.kr, S.H.L.), Korea University Ansan Hospital, Ansan, South Korea; Department of Radiology (S.B.C., Y.H.K.), Korea University Anam Hospital, Seoul, South Korea; Department of Radiology (T.S., M.G.S.), Korea University Guro Hospital, Seoul, South Korea.

Received 15 May 2018; accepted 21 June 2018.

DOI 10.5152/dir.2018.18225

You may cite this article as: Park S-J, Chung HH, Lee SH, et al. Long-term balloon indwelling technique for the treatment of single benign biliary stricture. *Diagn Interv Radiol* 2019; 25: 90–94.

Long-term balloon indwelling

The 0.035-inch guidewire (Radiofocus Guidewire, Terumo) and catheter (Impress, Merit medical) were used to pass through the benign biliary stricture site. Before inserting an internal drainage catheter (Multipurpose Drainage Catheter; Sungwon medical), dilatation of the stricture site was performed using balloon catheters (Mustang, Boston Scientific). Balloon dilatation was performed with a balloon size up to 10%–15% larger than the estimated diameter of the duct. After dilatation of the stricture site, drainage pigtail catheter with multiple side holes was inserted over the 0.035-inch guidewire through the stricture site for inducing internal biliary drainage. Then, a balloon catheter was inserted and allowed to escape through one of the side holes of the drainage catheter. The balloon was then inflated to the desired diameter at the target stricture site, which was 2 mm smaller than the diameter of the balloon catheter used for primary balloon dilatation. When balloon dilatation is performed, the fluid to be injected into the inflation port should be diluted 1:3 with contrast medium and normal saline. Injection of contrast agent without dilution into the inflation port of the balloon catheter can make deflation impossible due to hardening of the contrast agent. Because the balloon should be indwelled for a long time, the inflation port of the balloon catheter was locked using a one-way flow switch (FloSwitch HP, Boston Scientific), and a plaster was used to wrap the flow switch around the inflation port to minimize deflation. A Y-connector (Rotating Hemostatic Valve, Abbott) was used to hold the balloon and the drainage catheter together during the indwelling period, and the Y connector's valve was turned

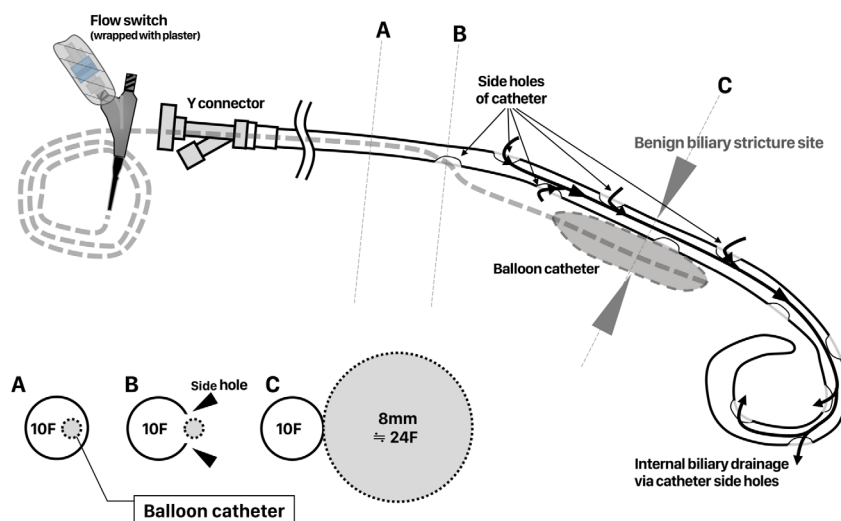


Figure 1. Schematic illustration of long-term balloon indwelling technique. After balloon dilatation of the stricture site, drainage pigtail catheter with multiple side holes was inserted over the 0.035-inch guidewire through the stricture site. Then a balloon catheter was inserted and allowed to come out through the side hole of the drainage catheter. The balloon was then inflated to the desired diameter at the target stricture site. Schematic drawings A, B, C show the axial view at each level corresponding to dotted lines.

to tighten. Then the drain catheter was sutured to the skin and fixed. The remaining balloon catheter on the outside of the Y connector was well rolled and attached to the skin during the indwelling period (Figs. 1 and 2).

We set up the follow-up protocol to call patients at least once every 2 weeks to evaluate the adequacy of expansion and location of the balloon catheter. The balloon was reinflated with some amount of saline at each follow-up session and removed after about 2 months of indwelling period. Blood chemistry, including serum bilirubin, alanine transaminase (ALT), aspartate aminotransferase (AST), and alkaline phosphatase level (ALP), was followed up for liver function testing. Clinical symptoms such as fever and pain were also evaluated during the follow-up period.

Evaluation

Primary technical success, maintenance of balloon location, removal success, and clinical success were evaluated. Primary technical success was defined as successful placement of balloon and catheter at the intended location of stricture site in the first procedure session. Successful removal of the balloon was also evaluated. Clinical success was defined as maintenance of normalized blood chemistry result and no evidence of patients' symptom related to bili-

ary obstruction until the end of indwelling period of 2 months. For evaluating clinical success or failure, leukocytosis, fever, chill, and elevation of blood chemistry data (bilirubin, ALT, AST, ALP) were evaluated.

After removal of the balloon catheter, the patient was routinely examined for signs of recurrence or abnormal blood chemistry through outpatient follow-up.

Results

Table 1 summarizes the patients' clinical characteristics, primary technical success, maintenance of balloon location, removal success, clinical success, and follow-up results.

In all five cases, the balloon and catheter were successfully positioned on the intended location of benign biliary stricture site in primary procedure session; therefore, the technical success rate was 100%.

According to the follow-up protocol before balloon removal, every patient should undergo follow-up fluoroscopic examination at least once every 2 weeks. Three patients (patients 1, 2, and 5) received five follow-up tubograms, and one patient (patient 3) received four follow-up tubograms. The other patient (patient 4) received seven evaluations until the balloon was removed. A total of 26 follow-up fluoroscopic examinations were performed in five patients. Displacement of balloon catheter was

Main points

- Treatment of benign biliary stricture requires the use of long-term indwelling treatment method.
- A long-term balloon indwelling technique is a good way to induce maximal dilatation at the stricture site without large diameter skin and subcutaneous tract dilatation and can be successfully used for single biliary strictures.
- This technique is able to induce larger diameter dilatation at the target benign biliary stricture site while performing smaller skin and subcutaneous dilatation than the previously described methods.

Table 1. Patients' clinical characteristics, used devices, the primary technical success, maintenance of balloon location, removal success, clinical success, and follow-up results

| Primary session of long-term balloon indwelling technique | | | | | Indwelling time ~Balloon catheter removal | | | | Follow-up | | | | | | | |
|---------------------------------------------------------------------------------------------------------------------------------------------------------------------------------------------------------------------------------------------------------------------------------------------------------------------------------------------------------------------------------------------------------------------------------------------------------------------------------------------------------------------------------------------------------------------------------|-----|-----------|----------------------------------------------------------------------------------------|------------------------------------------------------|-------------------------------------------|-----------------------------------|-------------------------------------------------|--------------------------------------------|----------------------|---------------------------|------------------------------------------------------------------------|-----------------------------------------------------------------------|-------------------------------------------------|---------------------|--------------------------------------------------------------|------------|
| Pa- tient No. | Sex | Age, y | Presumed cause of biliary stricture | Stricture site | Length of stricture site (mm) | Diameter of catheter (F) | Diameter of indwelling balloon (mm) | Length of indwelling balloon (mm) | Technical success | Indwelling time (days) | Follow-up fluoroscopies after placing the balloon catheter | Displacement of balloon catheter on follow-up fluoroscopy | Successful removal of balloon catheter | Clinical success | Follow-up period after balloon removal (days) | Recurrence |
| 1 ^a | F | 50 | Recurrent cholangitis | CBD | 19 | 10 | 8 | 40 | Yes | 64 | 5 | 1 ^b | Yes | Yes | 106 | No |
| 2 | M | 64 | PPPD with choledochojeju- nostomy d/t IPMN | Choledoch- jejunostomy anastomosis site | 11 | 10 | 6 | 60 | Yes | 59 | 5 | 0 | Yes | Yes | 1042 | No |
| 3 ^a | M | 41 | Choledochoje- junostomy d/t CBD injury during laparoscopic cholecystectomy | Choledoch- jejunostomy anastomosis site | 3 | 16 ^c | 8 | 60 | Yes | 57 | 4 | 0 | Yes | Yes | 743 | No |
| 4 ^a | F | 30 | Choledochal cyst type 1 excision | Hepaticojeju- nostomy site | 12 | 10 | 7 | 40 | Yes | 86 | 7 | 0 | Yes | Yes | 96 | No |
| 5 | M | 65 | Anterior sectionectomy of the liver | Between right posterior segment IHD and CBD | 14 | 10 | 4 | 20 | Yes | 56 | 5 | 0 | Yes | Yes | 724 | No |
| F, female; M, male; CBD, common bile duct; PPPD, pylorus preserving pancreaticoduodenectomy; IPMN, intraductal papillary mucinous neoplasm; IHD, intrahepatic duct. ^a Prior percutaneous biliary stone removal had been performed. ^b Balloon displacement was detected at one of five total follow-up fluoroscopies and immediately adjusted to the right position. ^c Prior percutaneous biliary stone removal had been performed with 16F catheter and we continued to use that catheter for long-term balloon indwelling technique. | | | | | | | | | | | | | | | | |

F, female; M, male; CBD, common bile duct; PPPD, pylorus preserving pancreaticoduodenectomy; IPMN, intraductal papillary mucinous neoplasm; IHD, intrahepatic duct.

^aPrior percutaneous biliary stone removal had been performed.^bBalloon displacement was detected at one of five total follow-up fluoroscopies and immediately adjusted to the right position.^cPrior percutaneous biliary stone removal had been performed with 16F catheter and we continued to use that catheter for long-term balloon indwelling technique.

detected at only 1 of 26 follow-up fluoroscopic examinations, but it was repositioned immediately. The other 25 follow-up fluoroscopic examinations in five patients showed no displacement of the balloon catheter. Therefore, maintenance of the balloon location was achieved in 25 of 26 follow-up tubograms with a rate of 96.1%.

No adverse symptoms or abnormal laboratory findings developed during the indwelling period in any of the patients, resulting in 100% (5/5) clinical success; successful balloon catheter removal after completion of indwelling time was also achieved in all five patients (100%). Pain was reported in patients on the day of the procedure or the next day, but oral analgesics was sufficient to relieve it. No patients complained of significant pain during follow-up.

The mean follow-up period after successful removal of the balloon was 542.2 days (93–1042 days), and there were no recurrences in any of the five cases in terms of laboratory findings and clinical symptoms.

Discussion

Treatment of benign biliary stricture is controversial. Various interventional radiological treatment methods have been developed. Balloon dilatation (1, 3–5) and stent insertion (5–7) have been described and used clinically. Percutaneous balloon dilatation followed by PTBD was revised, and the 3-year primary patency of treatment using balloon dilatation was reported as only 44% (6). For this reason, short-term interventional therapy was insufficient and long-term indwelling treatment method was needed. Therefore, catheter-indwelling techniques have emerged. Percutaneous management with a large-bore catheter indwelling method has been discussed (1, 8), and the dual catheter placement technique was published by Gwon et al. (2). However, these techniques need larger dilatation of the skin and subcutaneous tissues, are accompanied by pain, and dilatation at the stricture site is limited to the diameter of the inserted catheter.

We present a long-term balloon indwelling technique for the treatment of benign biliary stricture. In this technique, the size that induces inflation at the target stricture site is determined by the balloon diameter. Moreover, the catheter through skin and subcutaneous tissue can have a small profile, just enough to pass the balloon

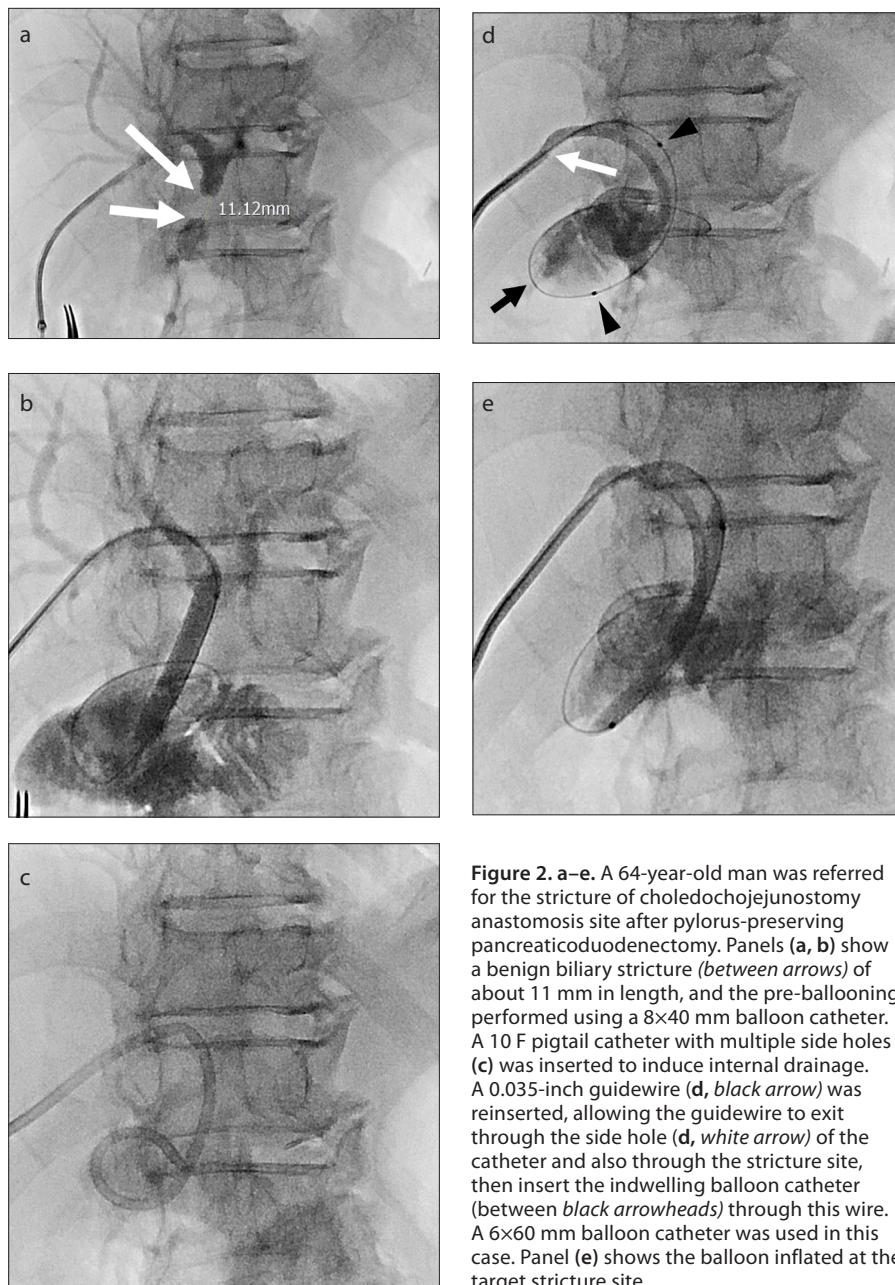


Figure 2. a–e. A 64-year-old man was referred for the stricture of choledochojejunostomy anastomosis site after pylorus-preserving pancreaticoduodenectomy. Panels (a, b) show a benign biliary stricture (between arrows) of about 11 mm in length, and the pre-balloon dilation performed using a 8×40 mm balloon catheter. A 10 F pigtail catheter with multiple side holes (c) was inserted to induce internal drainage. A 0.035-inch guidewire (d, black arrow) was reinserted, allowing the guidewire to exit through the side hole (d, white arrow) of the catheter and also through the stricture site, then insert the indwelling balloon catheter (between black arrowheads) through this wire. A 6×60 mm balloon catheter was used in this case. Panel (e) shows the balloon inflated at the target stricture site.

Table 2. The ease of balloon catheter passage according to the diameter of the drainage catheter

| Drainage catheter ^b | Balloon catheter ^a | | | |
|--------------------------------|-------------------------------|-----------------|-----------------|-----------------|
| | 8 mm | 9 mm | 10 mm | 12 mm |
| 8 F | Not fit | Not fit | Not fit | Not fit |
| 10 F | Enters smoothly | Enters smoothly | Enters smoothly | Tight |
| 12 F | Enters smoothly | Enters smoothly | Enters smoothly | Enters smoothly |
| 14 F | Enters smoothly | Enters smoothly | Enters smoothly | Enters smoothly |

^aBalloon catheter, Mustang (Boston Scientific).
^bDrainage catheter, Multipurpose drainage catheter (Sungwon Medical).

catheter (Fig. 1), which is usually about 10 F. Because of these procedural benefits, we believe that this technique has important advantages in pain management and treatment effectiveness of the stricture site.

Table 2 summarizes the ease of balloon catheter passage according to the diameter of the drainage catheter. In general, 10 F drainage catheters can easily accept the 10 mm balloon catheter. In this study, there was 1 patient using a 16 F drainage catheter. In that case, tract dilatation was required to remove the combined intrahepatic biliary stone, and the long-term balloon indwelling technique was performed.

However, now we think that this technique can only be applied to single benign biliary strictures. We may use a long balloon catheter to induce a therapeutic effect on multiple stricture sites, but the balloon catheter may have an unintended effect of blocking multiple hepatic biliary ducts that would need to drain internally through the multiple side holes of the drainage catheter.

There were several limitations in this study. First, this study design was retrospective. Second, there was no comparative arm. Third, the number of patients enrolled in this study was small, and additional studies and more cases are needed to further assess the feasibility of this method.

In conclusion, a long-term balloon indwelling technique is a good way to induce maximal dilatation at the stricture site without large diameter skin and subcutaneous tract dilatation and can be successfully used for single biliary stricture.

Conflict of interest disclosure

The authors declared no conflicts of interest.

References

1. Choo SW, Shin SW, Do YS, et al. The balloon dilatation and large profile catheter maintenance method for the management of the bile duct stricture following liver transplantation. *Korean J Radiol* 2006; 7:41–49. [\[CrossRef\]](#)
2. Gwon DI, Sung KB, Ko GY, Yoon HK, Lee SG. Dual catheter placement technique for treatment of biliary anastomotic strictures after liver transplantation. *Liver Transpl* 2011; 17:159–166. [\[CrossRef\]](#)
3. Lee AY, Gregorius J, Kerlan RK, Jr., Gordon RL, Fidelman N. Percutaneous transhepatic balloon dilation of biliary-enteric anastomotic strictures after surgical repair of iatrogenic bile duct injuries. *PloS one* 2012; 7:e46478. [\[CrossRef\]](#)
4. Righi D, Cesarani F, Muraro E, Gazzera C, Salizzoni M, Gandini G. Role of interventional radiology in the treatment of biliary strictures following orthotopic liver transplantation. *Cardiovascular Intervent Radiol* 2002; 25:30–35. [\[CrossRef\]](#)

5. Roumilhac D, Poyet G, Sergent G, et al. Long-term results of percutaneous management for anastomotic biliary stricture after orthotopic liver transplantation. *Liver Transpl* 2003; 9:394–400. [\[CrossRef\]](#)
6. Kim JH, Gwon DI, Ko G-Y, et al. Temporary placement of retrievable fully covered metallic stents versus percutaneous balloon dilation in the treatment of benign biliary strictures. *J Vasc Intervent Radiol* 2011; 22:893–899. [\[CrossRef\]](#)
7. Memeo R, Piardi T, Sangiuolo F, Sommacale D, Pessaux P. Management of biliary complications after liver transplantation. *World J Hepatol* 2015; 7:2890–2895. [\[CrossRef\]](#)
8. Ludwig JM, Webber GR, Knechtle SJ, Spivey JR, Xing M, Kim HS. Percutaneous Management of Benign Biliary Strictures with Large-Bore Catheters: Comparison between Patients with and without Orthotopic Liver Transplantation. *J Vasc Intervent Radiol* 2016; 27:219-25.e1. [\[CrossRef\]](#)